

Neuropathology associated with feline immunodeficiency virus infection highlights prominent lymphocyte trafficking through both the blood-brain and blood-choroid plexus barriers

Gavin Ryan,¹ Terence Grimes,² Brenda Brankin,^{3,4} Mohamad JEMF Mabruk,⁵ Margaret J Hosie,⁶ Oswald Jarrett,⁶ and John J Callanan^{1,4}

¹Department of Veterinary Pathology; and ²Small Animal Clinical Studies, Faculty of Veterinary Medicine; ³The Department of Biochemistry, Faculty of Science; and ⁴The Conway Institute of Biomolecular and Biomedical Research, University College Dublin, Dublin, Ireland; ⁵Advanced Medical and Dental Institute, University Sains Malaysia, Penang, Malaysia; ⁶Division of Infection and Immunity, Institute of Comparative Medicine, University of Glasgow, Bearsden, Glasgow, Scotland

Feline immunodeficiency virus (FIV) infection in the cat is a well-evaluated model of human immunodeficiency virus (HIV)-1 infection in man with both viruses associated with significant neuropathology. Although studies in both HIV and FIV infections have shown that virus enters the brain in the acute stages of disease, little is known of the mechanisms of viral entry. The dissection of this stage is fundamental to the development of therapies that may prevent or modulate central nervous system (CNS) infection. The present study was designed to characterize the early sequential neuropathological changes following infection with FIV_{GL8}, a strain known to enter the CNS in acute infection. Cats were infected either by the intraperitoneal ($n = 13$) or intravenous ($n = 12$) route with 2000 cat infectious units of virus. Histopathological assessments following intraperitoneal infections were at 4 ($n = 2$), 5 ($n = 1$), 8 ($n = 3$), 10 ($n = 1$), 16 ($n = 1$), 32 ($n = 2$), 52 ($n = 2$), and 104 ($n = 1$) weeks post infection whereas animals infected intravenously were examined ($n = 3$) at 1, 4, 10, and 23 weeks post infection. The most significant lesions following both routes of infection were lymphocyte-rich perivascular infiltrates within cerebral and cerebellar meninges, in choroid plexus and spinal cord dura mater and within epineurium of the sciatic nerve. In addition, following intravenous infection perivascular infiltrations were noted in parenchymal blood vessels primarily of cerebral white matter. Infiltrates were composed of CD79+ B cells and CD3+ T cells. The latter population contained a mixture of CD4+ and CD8+ cells. The severity of lesions increased in intensity in the 8- to 16-week period following infection and then began to wane. The evaluation of this large group of cats at multiple time points revealed pathology comparable with that of early stage HIV-1-associated encephalitis. Moreover, in contrast to previous FIV neuropathology studies, transient meningeal, choroid plexus, and parenchymal vascular pathology were consistent significant findings suggesting that, as in HIV-1 infection, blood-brain barrier and choroid plexus brain barrier integrity are both compromised in early infection. *Journal of NeuroVirology* (2005) 11, 337–345.

Keywords: HIV-1; mononuclear cells; neuropathology; perivascular cuffing

Address correspondence to Dr. John J. Callanan, Department of Veterinary Pathology, Faculty of Veterinary Medicine, University College Dublin, Belfield, Dublin 4, Ireland. E-mail: sean.callanan@ucd.ie

The authors acknowledge the technical assistance of colleagues in the Departments of Veterinary Pathology, University College Dublin (S. Worrall, B. Cloak, C. King, and J. Brady) and University of Glasgow (R. Irvine, I. McMillan, J. Cole). This work was funded by a Faculty of Veterinary Medicine, University College Dublin, Research Stimulus Grant and by the Wellcome Trust.

Received 14 March 2005; revised 6 May 2005; accepted 16 May 2005.

Introduction

Human immunodeficiency virus (HIV), the cause of acquired immunodeficiency syndrome (AIDS) in man, is neurotropic and responsible for considerable neuropathology and neurological disorders (Budka, 1991; Kanzer, 1990). To date, there have been limited opportunities to investigate the central nervous system (CNS) of patients in the early stages of HIV infection when virus invades the brain (Gray *et al*, 1996). It is agreed that the dissection of this early stage of infection is fundamental to the development of therapies that may prevent or modulate HIV-associated CNS pathology (Annunziata, 2003; Speth *et al*, 2005). To evaluate the sequence of immunological processes in early HIV-1 infection therefore requires the contributions of animal models.

Simian immunodeficiency virus (SIV) and feline immunodeficiency virus (FIV) are both considered excellent models of HIV-1 infection in man (Gardiner and Luciw, 1989; Overbaugh *et al*, 1997; Miller *et al*, 2000). FIV, like HIV-1, infects the central nervous system and is associated with neuropathology in natural and experimental infections (Dow *et al*, 1990, 1992; Hurtel *et al*, 1992; Podell *et al*, 1999). Early after intravenous inoculation, virus can be detected in the brain and cerebrospinal fluid (CSF), with *in vitro* studies demonstrating that FIV preferentially infects astrocytes and brain macrophages, with low affinity for brain endothelial cells (Yamamoto *et al*, 1988; Dow *et al*, 1990, 1992; Boche *et al*, 1996; Podell *et al*, 1997; Ryan *et al*, 2003). Although studies on FIV have shown that the acute phase of infection is a significant time during which virus invades the CNS, mechanisms by which the virus enters are unclear (Ryan *et al*, 2003; Boche *et al*, 1996; Poli *et al*, 1997).

The present study was designed to characterize early-stage sequential neuropathology changes in 25 cats during the first 2 years after either intraperitoneal or intravenous infection with the Glasgow-8 strain of FIV (FIV_{GL8}). This is the first documentation of neuropathology associated with FIV_{GL8}, a viral strain known to enter brain tissue in the acute phase of infection (Ryan *et al*, 2003). The evaluation of this large group of cats at multiple time points during infection revealed pathology comparable with that of early-stage HIV-1 infection and moreover, highlighted that, as in HIV-1 infection, both blood-brain barrier and blood-choroid plexus barrier facilitates lymphocyte trafficking into the CNS within weeks of infection.

Results

Histopathology

No neuropathology was observed in the control animals in either group. The severity and distribution of nervous system lesions associated with intraperitoneal or intravenous FIV infections are presented in Tables 1 and 2, respectively.

Following intraperitoneal infection, lesions consisted primarily of perivascular mononuclear cell infiltrations within the meninges of the brain, in the choroid plexus, in the dura of the spinal cord, and in the epineurium of the sciatic nerve. Occasionally diffuse infiltrates of the subarachnoid space were also identified. The cellular infiltrates were composed of small lymphocytes, blast cells, and plasma cells in variable numbers.

Perivascular infiltrates were identified in the cerebral and cerebellar meninges of 5 of 13 cases (Figure 1). In one case these were accompanied by a diffuse mononuclear cell infiltration of the

Table 1 Sites and severity of mononuclear cell infiltrates within neural tissue following intraperitoneal FIV infection

Ref. no.	Week PI	Clinical status	Brain		Spinal cord				PNS Sciatic nerve
			Meninges	Choroid	Cervical dura	Thoracic dura	Lumbar dura	Ganglion	
A1	4	As	–	–	–	–	na	–	+
A2	4	As	–	+	na	na	–	+	+
A3	5	Acute	–	–	–	++	–	+	na
A4	8	As	–	++	++	++	–	–	–
A5	8	As	++	++	++	+++	–	+	na
A6	8	Acute	–	+	–	–	–	–	+
A7	10	Acute	–	–	+	+	–	+	–
A8	16	As	+	+++	++	++	++	++	++
A9	32	Lympho	+	–	–	+	+	+	++
A10	32	As	+	+	+	+	+	–	++
A11	52	As	–	–	–	–	–	–	+
A12	52	As	+	+	+	+	+	+	+
A13	104	Lympho	–	–	–	–	–	+	+

As = asymptomatic; Acute = acute stage of infection characterised by pyrexia, dullness, unresponsiveness, and leucopenia; Lympho = lymphosarcoma.

PNS = peripheral nervous system; PI = post infection; na = no sample available.

Magnitude of mononuclear cell infiltrations: – = absent; + = minimal; ++ = mild; +++ = moderate.

Table 2 Sites and severity of mononuclear cells and presence of tissue and CSF viral and proviral loads following intravenous FIV infection

Ref. no.	Week PI	Clinical status	Brain			Spinal cord			PNS Sciatic nerve	Virus* tissue Viral RNA (copies/g)	Viral RNA (copies/ml)		Tissue Provirus copies/10 ⁶ cells
			Meninges	Neuropil	Choroid	Cervical dura	Thoracic dura	Lumbar dura			Plasma	CSF	
B1	1	As	-	-	-	na	-	-	-	152	-	-	-
B2	1	As	-	-	-	na	-	-	-	-	-	-	-
B3	1	As	-	-	-	-	-	-	-	-	-	-	-
B4	4	As	-	-	-	-	-	-	-	3 × 10 ⁴	1 × 10 ⁴	400	418
B5	4	As	-	+	+	-	-	-	-	-	77	37	244
B6	4	As	-	-	-	na	-	-	-	-	187	40	24
B7	10	As	++	++	++	-	+	+	+	2 × 10 ⁶	1 × 10 ³	7 × 10 ³	586
B8	10	As	+	++	+	na	-	+	-	5 × 10 ³	496	105	-
B9	10	As	+	+	+	-	-	+	-	5 × 10 ⁴	374	61	109
B10	23	As	+	++	++	-	-	+	-	316	-	151	-
B11	23	As	+	-	-	+	+	+	-	-	33	-	-
B12	23	As	+	+	+	-	+	+	-	456	-	22	-

*Viral and proviral loads modified from Ryan *et al* (2003) and evaluated based on highest load detected. As = asymptomatic; PNS = peripheral nervous system; PI = post infection; na = no sample available. Magnitude of mononuclear cell infiltrations: - = absent; + = minimal; ++ = mild; +++ = moderate.

subarachnoid space. Infiltrates varied from single foci of 10 to 15 cells to larger infiltrates of up to 50 cells. Although lesions varied in severity between cases at individual time points, in general infiltrates were more prominent when first seen at 8 weeks after infection and thereafter decreased in severity up to week 52. By 2 years these lesions were absent and only calcification of meningeal blood vessels was occasionally noted.

The most prominent lesions within the brain of cats infected by intraperitoneal inoculation were choroid plexus infiltrates which were present in 7 of 13 cases examined. Infiltrates varied from 5 to 10 cells, to moderate numbers of 20 to 30 cells, to multiple and larger infiltrates of over 50 cells (Figure 2). The lesions were identified at 4 weeks, the first time point of sacrifice, and increased in severity in the 8- to 16-week period, returning to mild levels by week 52 and were absent by 2 years after infection.

Spinal lesions consisted of infiltrates in the dura, increased subarachnoid cellularity, and perivascular infiltrates in the connective tissue surrounding dorsal root ganglia and spinal nerve roots. Dural infiltrates were identified in 8 of 13 cases and varied from small infiltrates of 3 to 5 cells accompanied by prominent dural vascularity to much larger perivascular or diffuse infiltrations of up to 20 cells. Lesions were of greatest severity between weeks 5 and 16. The lesions were absent by 2 years after infection. Increased spinal subarachnoid cellularity was also a feature noted in six of these cases. Perivascular infiltrates in the connective tissue surrounding the spinal nerve roots and ganglia were present at one or all levels of the cord in eight of the cases from 4 weeks to 2 years after infection. Severity did not vary greatly with progression of infection.

The sciatic nerve was examined in 11 cases and lesions consisting of perivascular infiltrates in the

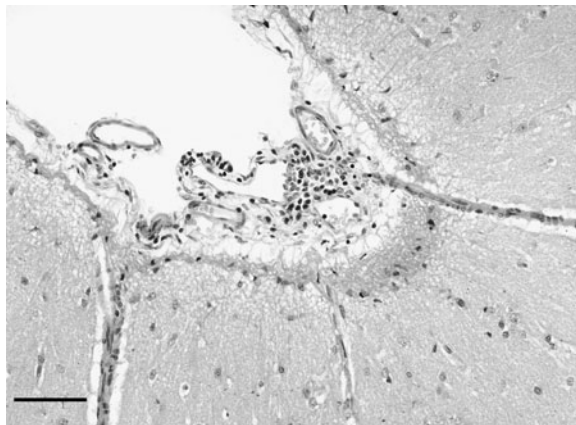


Figure 1 Case A5. Mild meningeal perivascular mononuclear cell infiltrations at eight weeks following intraperitoneal FIV infection. Hematoxylin & eosin. Bar = 100 μm.

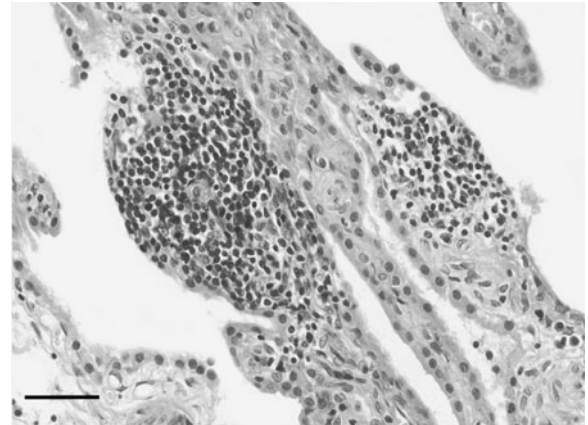


Figure 2 Case A8. Prominent choroid plexus mononuclear cell infiltrations at 16 weeks following intraperitoneal FIV infection. Hematoxylin & eosin. Bar = 50 μm.

epineurium or surrounding fat were identified in 9 cases. These were of greatest severity between weeks 16 and 32, where larger foci of more than 100 cells were present in the fat adjacent the epineurium. Milder lesions were still evident at 1 to 2 years after infection.

Two animals (A9, A13) developed lymphosarcoma (Callanan *et al*, 1996) but neither had tumour involvement within the CNS.

Lesions following intravenous infection were similar to those as a result of intraperitoneal infection. Perivascular mononuclear cell infiltrates were observed within the meninges of the brain, in the choroid plexus, in the dura mater of the spinal cord, occasionally within the epineurium of the sciatic nerve, and as diffuse infiltrations of the subarachnoid space. In contrast to the intraperitoneal infection, perivascular infiltrates were also observed around blood vessels within the white matter of the cerebrum and cerebellum (Figure 3).

Meningeal infiltrations were first noticed at week 10 following infection and were present in all infected animals at this time point and at week 23. With the exception of a single animal (B7), these infiltrates were mild, usually consisting of aggregations of less than 10 cells. Choroid plexus infiltrations were initially noticed in one animal by 4 weeks after infection and in five of six animals at the remaining time periods. In one animal, in each of these time periods, lesions were of moderate severity containing multiple aggregations of greater than 40 cells. A positive correlation between the presence of choroid plexus infiltration and perivascular infiltrations within brain white matter was noted. The parenchymal perivascular infiltrations varied from mild lesions of less than 20 cells to moderate lesions of over 40 cells, often involving multiple blood vessels. Invariably lesions were noted within white matter of the cerebral cortex. Occasionally lesions were also noted within cerebellar white matter and on one occasion in cerebrocor-

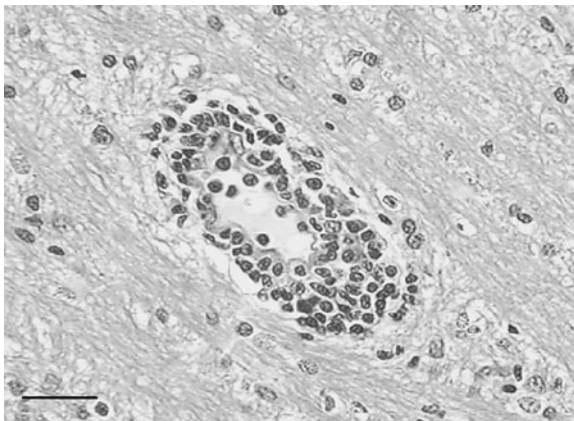


Figure 3 Case B7. Brain parenchymal perivascular mononuclear cell infiltrations at 10 weeks following intravenous FIV infection. Hematoxylin & eosin. Bar = 25 μ m.

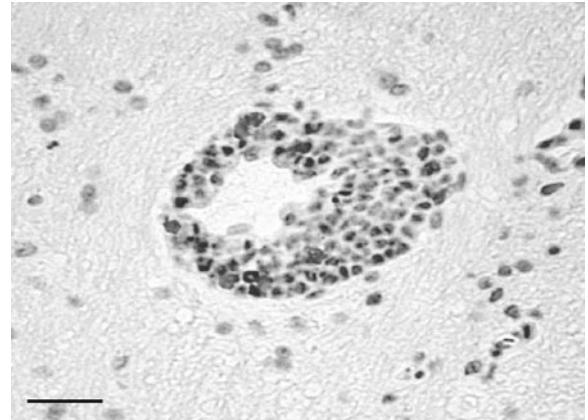


Figure 4 Case B7. CD79 α + B lymphocytes within brain parenchymal mononuclear cell infiltrates and in the parenchyma at 10 weeks following intravenous FIV infection. Hematoxylin. Bar = 25 μ m.

tical grey matter (B8). As with intraperitoneal infection, dural infiltrations were noted in all animals from 10 weeks post infection. This was accompanied by prominent diffuse subarachnoid infiltrations in two animals (B7, B9). Infiltrations within the epineurium of the sciatic nerve were observed in only one animal (B7), at 10 weeks after infection. Dorsal root ganglia were not examined in this study.

By routine light microscopy evaluations of hematoxylin and eosin (H&E) and luxol fast blue stained sections, no appreciable gliosis or white matter pallor was noted. There was no evidence of vasculitis in either group.

Immunohistochemistry of perivascular mononuclear cells

Immunohistochemical analysis of the perivascular cell infiltrations revealed that they were composed of CD79 α + B cells (Figure 4) and CD3+ T cells (Figure 5). This population of T cells contained

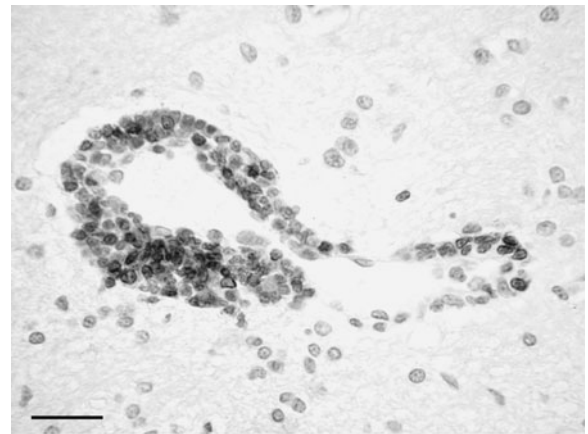


Figure 5 Case B7. CD3+ T lymphocytes within the brain parenchymal mononuclear cell infiltrates at 10 weeks following intravenous FIV infection. Hematoxylin. Bar = 25 μ m.

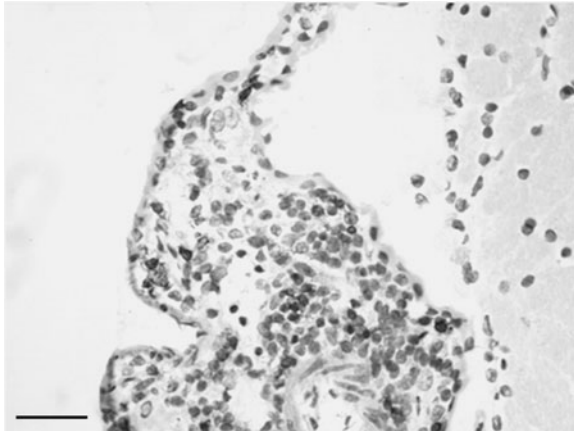


Figure 6 Case B7. CD8+ T lymphocytes within the choroid plexus mononuclear cell infiltrates at 10 weeks following intravenous FIV infection. Hematoxylin. Bar = 25 μ m.

subpopulations of both CD4+ and CD8+ cells (Figure 6). Mac 387+ macrophages were not observed within these infiltrates.

Correlation of histopathology to viral and proviral loads

Viral (brain tissue, CSF, and plasma) and proviral (brain tissue and peripheral blood mononuclear cell) loads were determined in animals that had been infected intravenously and a correlation of these findings with histopathological changes has been published (Ryan *et al*, 2003) and a modification of these results are presented in Table 2. In summary, by week 4 after infection, although it was possible to consistently detect either virus or provirus in CNS tissue or CSF, histopathology was relatively mild and a rare observation. In contrast at 10 and 23 weeks, both pathological changes and virus were detected consistently in all but one animal (B11). A comparison between plasma, CSF, and brain tissue viral loads highlighted that at the 10-week time point post, infection viral loads were at their highest within regions of brain tissue. It was also at this time point that the most intense pathology was noted. A positive correlation between the presence of choroid plexus pathology and the presence of viral RNA in CSF was noted in 10 of 12 animals (exceptions B4, B6). Although a trend existed for histopathological lesions and viral loads to increase in intensity and then diminish during the course of infection, a direct correlation between the magnitude of the cell infiltrations and the brain viral loads could not be consistently established. For example two animals (B7, B10) developed similar pathological features. For animal B7, this coincided with markedly elevated viral loads, but in animal B10, viral loads were considerably lower and similar to those of animal B12, which had minimal pathology. In addition, animal B4 had no detectable lesions in the presence of viral and proviral loads, whereas animal B11 at 23 weeks after infec-

tion had no detectable virus or provirus but had brain lesions.

Discussion

Neuropathology in the early stages of HIV-1 infection is characterized by meningeal, parenchymal, and choroid plexus perivascular lymphocyte cell-rich infiltrations, accompanied by vasculitis and immune activation of the brain parenchyma, with increased numbers of microglial cells, up-regulation of major histocompatibility complex class II molecules and local production of cytokines (Gray *et al*, 1996). Myelin pallor and gliosis are also features noted. In the present study both intraperitoneal and intravenous infections with FIV_{GL8} resulted in significant consistent meningeal and choroid plexus pathology. However, gliosis, myelin pallor, and vasculitis were not noted in this study.

A limited number of time-course studies to characterize the neuropathology in the early stages of FIV infection have been performed and, in contrast to HIV and SIV infections, meningeal and choroid plexus lesions have rarely been reported (Hurtel *et al*, 1992; Abramo *et al*, 1995; Boche *et al*, 1996; Poli *et al*, 1997). However, in the present study meningeal infiltrates were documented in 11 of 25 animals. These findings contrast previous studies in which meningeal involvement was rare (Hurtel *et al*, 1992; Boche *et al*, 1996; Power *et al*, 1998; Mitchell *et al*, 1999) in infections with Envip, Petaluma, Baltimore, Villefranche strains and not observed in studies on intravenous inoculations of PISA-M2 or Petaluma strains (Abramo *et al*, 1995; Poli *et al*, 1997). Similarly, in the present study perivascular infiltrates in the choroid plexus were frequent findings observed in 13 of 25 animals, in contrast to previous studies where such observations were noted infrequently (Hurtel *et al* 1992; Beebe *et al*, 1994).

Similar to early-stage HIV infection, the lymphocyte-rich infiltrations were composed of mixtures of T and B cells; however, unlike the CD8+ T cell-rich infiltrations in HIV, infiltrates contained mixtures of both CD4+ and CD8+ T cells (Gray *et al*, 1996; Anthony *et al*, 2003). Findings of B cells and plasma cells within the infiltration further supported the recent observations that B cells regularly traffic the CNS in many stages of HIV infection (Anthony *et al*, 2003) and in other viral-related encephalitic conditions (Esiri *et al*, 1989). In addition, the observations of plasma cells supported previous FIV studies that highlighted intrathecal antibody synthesis early in FIV infection (Dow *et al*, 1990; Podell *et al*, 1993). The early stages of SIV infection also observe cell infiltrations in white and gray matter, in the choroid plexus, and in the meninges. However, such infiltrations are not primarily lymphoid but are rich in CD68+ macrophages (Bottiger *et al*, 1991; Hurtel *et al*, 1991, 1993; Sharer *et al.*, 1991; Boche *et al*, 1999).

In animals that were intravenously infected with FIV_{GL8} parenchymal perivascular infiltrations were also noted. Such infiltrations were not seen in animals following intraperitoneal infection. Although initial viral loads administered to animals were similar in both groups, a relative difference existed as the animals receiving the intravenous doses were younger (4 to 5 months of age) compared to those receiving the intraperitoneal administrations (11 to 14 months). Therefore relative to animal weights it is likely that the group with parenchymal perivascular cuffing received a larger dose. However, although the route of administration and relative doses may have had the potential to increase the distribution of perivascular infiltration, the severity of all perivascular infiltrates were not appreciably different between either group. In addition, both groups also documented infiltrates of similar magnitudes in the spinal cord dura, in connective tissue surrounding dorsal root ganglia, and in the epineurium and surrounding fat of peripheral nerves. Therefore, in support of other studies, both the onset and severity of these lesions were, for the most part, similar irrespective of the methods of inoculation; however, in contrast to previous studies, lesions were progressive, being prominent for periods of time and then regressing towards the end of the first year of infection (Hurtel *et al*, 1992; Abramo *et al*, 1995; Boche *et al*, 1996; Poli *et al*, 1997). In early FIV infection, it would be desirable to undertake time-course studies to evaluate the dynamics of the various cell populations within the perivascular infiltrations and correlate any changes with viral and proviral loads. However, in the current study, the numbers of cases with suitable samples to facilitate multiple antigen profiling were limited and periods between tissue examinations were too long to make any meaningful conclusions.

Gliosis and myelin pallor were not observed in the present study. Surprisingly, by standard histopathological examinations appreciable gliosis was not noted; however, gliosis and glial nodule formation have been almost consistently documented in early infection with many FIV isolates (Hurtel *et al*, 1992; Boche *et al*, 1996; Poli *et al*, 1997; Mitchell *et al*, 1999). In these studies immunohistochemical, morphometrical, and stereological methods clearly enhance the abilities to confirm subtle gliosis and would be required in the present study before mild gliosis and astrocyte activation are truly discounted. The absence of white matter pallor was not of concern as it appears to be an inconsistent finding in early FIV infection and has been documented as a rare observation in some studies (Hurtel *et al*, 1992; Boche *et al*, 1996), but not seen in others (Podell *et al*, 1993; Poli *et al*, 1997; Power *et al*, 1998; Mitchell *et al*, 1999).

The acute stages of HIV, SIV, and FIV infections represent a time during which virus readily enters the CNS (Chiodi and Fenyo 1991; Sharer *et al*, 1991; Boche *et al*, 1999; Ryan *et al*, 2003), and it is during this period that FIV-associated neuropathol-

ogy infection mimics HIV-associated neuropathology by revealing prominent lymphocytic perivascular infiltration of meninges, choroid plexus, and brain parenchyma (Gray *et al*, 1996). Although the pathways used by blood-borne viruses to leave the bloodstream and invade the CNS are complex (Tyler and Gonzalez-Scarano, 1997; Annunziata, 2003), it is clear that in HIV, SIV, and FIV infections some of the perivascular lymphocytes or macrophages harbor virus (Sharer *et al*, 1991; Lackner *et al*, 1991; Davis *et al*, 1992; Hurtel *et al*, 1993; Boche *et al*, 1996). The present study highlighted that T- and B-lymphocyte trafficking through the blood-brain and blood-choroid plexus barriers is a consistent and probably time-dependent finding in early FIV infection. Whether such cells enter through disrupted barriers or whether their trafficking through the barrier is facilitated because of lymphocyte cell activation remains unclear (Hickey, 1991).

In HIV and SIV infections, blood-brain barrier disruption has been observed in association with encephalitis, but it is not clear if disruption precedes and facilitates cell trafficking into the CNS or occurs due to the chronic presence of macrophages around cerebral blood vessels in encephalitic states (Dallasta *et al*, 1999; Luabeya *et al*, 2000; Annunziata, 2003; MacLean *et al*, 2004; Speth *et al*, 2005). More recently, transient barrier disruption has been shown in association with the acute phase of a pathogenic simian-human immunodeficiency virus infection (Stephens *et al*, 2003) and detailed sequential neuropathological studies would be feasible in the FIV_{GL8} model in which the histopathological findings that we observed would indicate that disruptions in blood-brain barrier integrity may occur within the first 10 weeks of infection. A value of the FIV model maybe that it would complement the SIV model as the lymphocyte-rich cell population observed in FIV infection may more accurately mimic the changes observed in early-stage HIV infection (Gray *et al*, 1996). To date, although blood-brain barrier disruption has yet to be demonstrated in FIV infection at a morphological level, studies have revealed a loss of integrity through the measurement of albumin quotients from 2 to 4 months after infection (Dow *et al*, 1990; Podell *et al*, 1993). These findings correlates well with the initial development of perivascular infiltrations within brain, meningeal, and choroid plexus regions observed in the present study.

Alternatively, entry of viral agents to the CNS may be achieved through the choroid plexus (Segal, 2000). Transport of virus across the choroid plexus epithelial cells provides virus direct access to the cerebrospinal fluid, allowing virus to spread to the ependymal cells and adjacent brain tissue. In view of the fact that inflammatory infiltrations of the choroid plexus are also observed in early HIV-1 and SIV infections (Sharer *et al*, 1991; Gray *et al*, 1996) and clearly in the present study represent a consistent finding in early stage FIV_{GL8} infection, it must also

be considered that the choroid plexus route of entry equally warrants investigation. In addition, in the intravenously infected animals viral RNA was consistently detected in CSF from 4 weeks after infection, in association with the first observations of choroids plexus pathology (Ryan *et al*, 2003). It is known that choroid plexus cells can be infected with HIV (Harouse *et al*, 1989; Petito *et al*, 1999) and in the SIV and FIV models, virus is observed within choroid plexus tissues *in vivo* (Lackner *et al*, 1991; Beebe *et al*, 1994). Recent work by Bragg and colleagues (2002) reported FIV infection of choroid plexus macrophage-enriched cultures with the ability to infect cocultured feline T lymphocytes.

It has been postulated that perivascular infiltrations within the CNS in many viral diseases, including in early HIV-1 infection, are likely to reflect a systemic immune response (Gray *et al*, 1996). Previous studies have shown that either immune-activated or HIV-1-infected monocytes may traverse *in vitro* models of the blood-brain barrier (Persidsky *et al*, 1997; Weiss *et al*, 1999; Hickey, 1999) and that in fact such perivascular infiltrates are unlikely to represent a response to local HIV-1 infection but rather reflect a more systemic response, which provides a vehicle in which the cell-associated virus may be disseminated throughout the body. Supporting this theory, in the present study the pathological changes were transient and of greatest severity in the 8- to 16-week period following infection. This period of time coincided with the onset of generalized reactive lymphoid hyperplasia and immune stimulation experienced by cats infected with FIV_{GL8} (Callanan *et al*, 1993; Flynn *et al*, 1994) and this immune response wanes during the first year of infection in parallel with the regressing pathological changes observed in this study. Furthermore, perivascular mononuclear cell infiltrations were not exclusively confined to the CNS but were also observed in the connective tissue of the dorsal root ganglia, the epineurium of the peripheral nerve, and within non-neural tissues, suggesting generalized stimulation of the immune system. The lesions were of similar severity to those within the CNS and regressed with no evidence of residual damage. Further supporting an immune-driven pathological response rather than a local reaction to virus was the finding that in individual animals in group 2, the severity of pathology observed did not correlate with the viral burdens within the CNS and CSF during the first 23 weeks following intravenous infection (Ryan *et al*, 2003).

The present studies clearly indicate that early viral entry to the CNS in FIV_{GL8} infection induces neuropathology that mimics that of early HIV-1 infection. In this period, lesions suggest compromises in blood-brain and blood-choroid plexus barriers facilitating mononuclear cell migration into brain. Therefore the FIV model provides an ideal opportunity to dissect and elucidate the complex and probably multifaceted mechanisms by which virus enters and traffics through brain tissue.

Material and methods

Experimental animals and project design

Two groups of animals were used. Group 1 (A1 to A13) comprised 13, 11- to 14-month-old specific pathogen-free cats infected intraperitoneally with 2000 infectious unit doses of FIV_{GL8}. Animals were sacrificed at 4 ($n = 2$), 5 ($n = 1$), 8 ($n = 3$), 10 ($n = 1$), 16 ($n = 1$), 32 ($n = 2$), 52 ($n = 2$), or 104 ($n = 1$) weeks after infection. Five aged-matched controls, held in a separate but similar-type environment, were sacrificed at 4, 8, 16, 32, or 52 weeks only. All animals were in good health at the time of postmortem examination with the exception of three animals (A3, A6, A7), which became dull and febrile between weeks 5 and 10 of infection and were euthanased during these periods. Two animals (A9, A13) had lymphosarcoma at the time of postmortem examination. Clinical and some aspects of the pathology of these animals have been reported elsewhere (Callanan *et al*, 1992a, 1992b, 1996).

Animals in group 2 (B1 to B12) were part of a study to define central nervous system viral loads in the early stages of FIV infection (Ryan *et al*, 2003). Twelve, 16- to 20-week-old specific pathogen-free cats were infected intravenously with a similar dose of FIV_{GL8} to those in group 1 and were sacrificed in groups of three at 1, 4, 10, or 23 weeks after infection. Eight aged-matched control animals, housed separately in a similar environment, were sacrificed in groups of two at similar time periods. All animals appeared in good health at all times.

Postmortem, histopathological, and immunohistochemical examinations

At postmortem examination mid-sagittal sectioning of the brain was performed. One portion was fixed in neutral-buffered formalin and the second portion separated into cerebrum, cerebellum, and brainstem, snap-frozen in liquid nitrogen, and stored at -80°C . Sections of cervical, thoracic, and lumbar spinal cord, including dorsal root ganglia, were also fixed in neutral-buffered formalin. Sciatic nerve was also sampled.

Following fixation in formalin, sections of cerebrum, cerebellum, midbrain, pons, medulla, spinal cord, and nerve were paraffin-embedded, cut at $4\ \mu\text{m}$, and stained with hematoxylin and eosin. Selected sections were also stained with luxol fast blue. To phenotype cell infiltrations immunostaining was performed on both paraffin-embedded and cryostat sections as previously described (Callanan *et al*, 1996) using antibodies specific for T and B lymphocytes, namely CD3 (rabbit anti-CD3; Dako, UK), CD79 α (mouse anti-CD79 α ; Dako, UK), CD4 and CD8 (mouse anti-CD4 and -CD8; Dako, UK), and for macrophages and neutrophils, MAC387 (mouse anti-human histiocyte; Dako, UK). Detection of primary antibodies was performed using the Vectastain Elite Mouse and Rabbit kits (Vector Laboratories, UK) as per manufacturer's instructions.

References

- Abramo F, Bo S, Grazia Canese M, Poli A (1995). Regional distribution of lesions in the central nervous system of cats infected with feline immunodeficiency virus. *AIDS Res Hum Retroviruses* **11**: 1247–1253.
- Annunziata P (2003). Blood-brain barrier changes during invasion of the central nervous system by HIV-1: old and new insights into the mechanisms. *J Neurol* **250**: 901–906
- Anthony IC, Crawford DH, Bell JE (2003). B lymphocytes in the normal brain: contrasts with HIV-associated lymphoid infiltrates and lymphomas. *Brain* **126**: 1058–1067.
- Beebe AM, Dua N, Faith TG, Moore PF, Pedersen NC, Dandekar S (1994). Primary stage of feline immunodeficiency virus infection: dissemination and cellular targets. *J Virol* **68**: 3080–3091.
- Boche D, Hurtrel M, Gray F, Claessens-Maire MA, Ganière JP, Montagnier L, Hurtrel B (1996). Virus load and neuropathology in the FIV model. *J NeuroVirol* **2**: 377–387.
- Boche D, Khatissian E, Gray F, Falanga P, Montagnier L, Hurtrel B (1999). Viral load and neuropathology in the SIV model. *J NeuroVirol* **5**: 232–240.
- Bottiger D, Keys B, Putkonen P, Walther L, Fenyo EM, Norrby E, Ober B, Chiodi F (1991). Simian immunodeficiency virus (SIVsm) isolation from blood and brain of experimentally infected macaques. *AIDS* **5**: 445–449.
- Bragg DC, Childers TA, Tompkins MB, Tompkins WA, Meeker RB (2002). Infection of the choroids plexus by feline immunodeficiency virus. *J NeuroVirol* **8**: 211–224.
- Budka H (1991). Neuropathology of human immunodeficiency virus infection. *Brain Pathol* **1**: 163–175.
- Callanan JJ, Jones BA, Irvine J, Willett BJ, McCandlish IAP, Jarrett O (1996). Histological classification and immunophenotype of lymphosarcomas in cats with naturally and experimentally acquired Feline immunodeficiency virus infections. *Vet Pathol* **33**: 264–272.
- Callanan JJ, McCandlish IAP, O'Neil B, Lawrence CE, Rigby M, Pacitti AM, Jarrett O (1992a). Lymphosarcoma in experimentally induced feline immunodeficiency virus infection. *Vet Rec* **130**: 293–295.
- Callanan JJ, Racz P, Thompson H, Jarrett O (1993). Morphological characterisation of the lymph node changes in feline immunodeficiency virus infection as an animal model of AIDS. In: *Animal models of HIV infection*. Racz P, Letvin NL, Gluckmann JC (eds). Basel: Karger, pp 115–136.
- Callanan JJ, Thompson H, Toth SR, O'Neil B, Lawrence CE, Willett B, Jarrett O (1992b). Clinical and pathological findings in feline immunodeficiency virus experimental infection. *Vet Immunol Immunopathol* **35**: 3–13.
- Chiodi F, Fenyo EM (1991). Neurotropism of human immunodeficiency virus. *Brain Pathol* **1**: 185–191.
- Dallasta LM, Pizarov LA, Esplen JE, Werley JV, Moses AV, Nelson JA, Achim CL (1999). Blood-brain barrier tight junction disruption in human immunodeficiency virus-1 encephalitis. *Am J Pathol* **155**: 1915–1927.
- Davis LE, Hjelle BL, Miller VE, Palmer DL, Llewellyn AL, Merlin TL, Young SA, Mills RG, Wachsmann W, Wiley CA (1992). Early viral brain invasion in iatrogenic human immunodeficiency virus infection. *Neurology* **42**: 1736–1739.
- Dow SW, Dreitz MJ, Hoover EA (1992). Feline immunodeficiency virus neurotropism: evidence that astrocytes and microglia are the primary target cells. *Vet Immunol Immunopathol* **35**: 23–35.
- Dow SW, Poss ML, Hoover EA (1990). Feline immunodeficiency virus: a neurotropic lentivirus. *J Acquir Immune Defic Syndr* **3**: 658–668.
- Eisiri MM, Reading MC, Squier MV, Highes JT (1989). Immunocytochemical characterisation of the macrophage and lymphocyte infiltration in the brain of six cases of human encephalitis of varied aetiology. *Neuropathol Appl Neurobiol* **15**: 289–305.
- Flynn JN, Cannon CA, Lawrence CE, Jarrett O (1994). Polyclonal B-cell activation in cats infected with feline immunodeficiency virus. *Immunology* **81**: 626–630.
- Gardiner MB, Luciw PA (1989). Animal models of AIDS. *FASEB J* **3**: 2593–2606.
- Gray F, Scaravilli F, Everall I, Chrétien F, An S, Boche D, Adle-Biassette H, Wingertsman L, Durigon M, Hurtrel B, Chiodo F, Bell J, Lantos P (1996). Neuropathology of early HIV-1 infection. *Brain Pathol* **6**: 1–15.
- Harouse JM, Wroblewska Z, Laughlin MA, Hickey WF, Schonwetter BS, Gonzalez-Scarano F (1989). Human choroids plexus cells can be latently infected with human immunodeficiency virus. *Ann Neurol* **25**: 406–411.
- Hickey W (1999). Leukocyte traffic in the central nervous system: the participants and their roles. *Semin Immunol* **11**: 125–137.
- Hickey WF (1991). Migration of hematogenous cells through the blood-brain barrier and the initiation of CNS inflammation. *Brain Pathol* **1**: 97–105.
- Hurtel B, Chakrabarti L, Hurtel M, Maire MA, Dormont D, Montagnier L (1991). Early SIV encephalopathy. *J Med Primatol* **20**: 159–166.
- Hurtel B, Chakrabarti L, Hurtel M, Montagnier L (1993). Target cells during early SIV encephalopathy. *Res Virol* **144**: 41–46.
- Hurtel M, Ganière JP, Guelfi JF, Chakrabarti L, Maire MA, Gray F, Montagnier L, Hurtrel B (1992). Comparison of the early and late feline immunodeficiency virus encephalopathies. *AIDS* **6**: 399–406.
- Kanzer MD (1990). Neuropathology of AIDS. *Crit Rev Neurobiol* **5**: 313–362.
- Lackner AA, Dandekar S, Gardner MB (1991). Neurobiology of simian and feline immunodeficiency virus infections. *Brain Pathol* **1**: 210–212.
- Luabeya MK, Dallasta LM, Achim CL, Pauza CD, Hamilton RL (2000). Blood-brain barrier disruption in simian immunodeficiency virus encephalitis. *Neuropathol Appl Neurobiol* **26**: 454–462.
- MacLean AG, Rasmussen TA, Bieniemy DN, Alvarez X, Lackner AA (2004). SIV-induced activation of the blood-brain barrier requires cell-associated virus and is not restricted to endothelial cell activation. *J Med Primatol* **33**: 236–242.
- Millar RJ, Cairns JS, Bridges S, Sarvar N (2000). Human immunodeficiency virus and AIDS: Insights from animal lentiviruses. *J Virol* **74**: 7187–7195.
- Mitchell TW, Buckmaster PS, Hoover EA, Whalen LR, Dudek FE (1999). Neuron loss and axon reorganization in the dentate gyrus of cats infected with feline immunodeficiency virus. *J Comp Neurol* **411**: 563–577.

- Overbaugh J, Luciw PA, Hoover EA (1997). Models for AIDS pathogenesis: simian immunodeficiency virus, simian-human immunodeficiency virus and feline immunodeficiency virus infections. *AIDS* **11(Suppl A)**: S47–S54.
- Persidsky Y, Stins M, Way D, Witte MH, Weinand M, Kim KS, Bock P, Gendelman HE, Fiala M (1997). A model for monocyte migration through the blood-brain barrier during HIV-1 encephalitis. *J Immunol* **158**: 3499–3510.
- Petito CK, Chen H, Mastro AR, Torres-Muniz J, Roberts B, Wood C (1999). HIV infection of choroids plexus in AIDS and asymptomatic HIV infected patients suggests that the choroids plexus may be a reservoir of productive infection. *J NeuroVirol* **5**: 670–677.
- Podell M, Hayes K, Oglesbee M, Mathes L (1997). Progressive encephalopathy associated with CD4/CD8 inversion in adult FIV-infected cats. *J Acquir Immune Defic Syndr Hum Retrovirol* **15**: 332–340.
- Podell M, March P, Buck W, Hayes K, Oglesbee M, Steigerwald E, Mathes L (1999). The feline model of neuroAIDS, part 2. *NeuroAIDS* **2**: 1–6.
- Podell M, Oglesbee M, Mathes L, Krakowka S, Olmstead R, Lafrado L (1993). AIDS-associated encephalopathy with experimental feline immunodeficiency virus infection. *J Acquir Immune Defic Syndr* **6**: 758–771.
- Poli A, Abramo F, DiLorio C, Cantile C, Carli MA, Pollera C, Vago L, Tosoni A, Costanzi G (1997). Neuropathology in cats experimentally infected with feline immunodeficiency virus: a morphological, immunocytochemical and morphometric study. *J NeuroVirol* **3**: 361–368.
- Power C, Buist R, Johnston JB, DelBigo MR, Ni W, Dawood MR, Peeling J (1998). Neurovirulence in feline immunodeficiency virus-infected neonatal cats is viral strain specific and dependent on systemic immune suppression. *J Virol* **72**: 9109–9115.
- Ryan G, Klein D, Knapp E, Hosie MJ, Grimes T, Mabruk MJEMF Jarrett O, Callanan JJ (2003). Dynamics of viral and proviral loads of feline immunodeficiency virus within the feline central nervous system during the acute phase following intravenous infection. *J Virol* **77**: 7477–7485.
- Segal MB (2000). The choroid plexuses and the barriers between the blood and cerebrospinal fluid. *Cell Mol Neurobiol* **20**: 183–196.
- Sharer LR, Michaels J, Murphy-Corb M, Hu FS, Kuebler DJ, Martin LN, Baskin GB (1991). Serial pathogenesis study of SIV brain infection. *J Med Primatol* **20**: 211–217.
- Speth C, Dierich MP, Sopper S (2005). HIV-infection of the central nervous system: the tightrope walk of innate immunity. *Mol Immunol* **42**: 213–228.
- Stephens EB, Singh DK, Kohler ME, Jackson M, Pacyniak E, Berman NE (2003). The primary phase of infection by pathogenic simian-human immunodeficiency virus results in disruption of the blood-brain barrier. *AIDS Res Hum Retroviruses* **19**: 837–846.
- Tyler KL, Gonzalez-Scarano F (1997). Viral diseases of the central nervous system. In: *Viral pathogenesis*. Nathanson N, Ahmed R, Gonzalez-Scarano F, Griffin DE, Holmes KV, Murphy FA, Robinson HL (eds). Philadelphia: Lippincott. Raven, pp 837–853.
- Weiss JM, Nath A, Major EO, Berman JW (1999). HIV-Tat induces monocyte chemoattractant protein-1-mediated monocyte transmigration across a model of the human blood-brain barrier and up-regulates CCR5 expression on human monocytes. *J Immunol* **163**: 2953–2955.
- Yamamoto JK, Sparger E, Ho EW, Anderson PR, O'Connor TP, Mandell CP, Lowenstine L, Munn R, Pedersen NC (1988). The pathogenesis of experimentally induced feline immunodeficiency virus infection. *Am J Vet Res* **49**: 1246–1258.